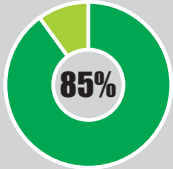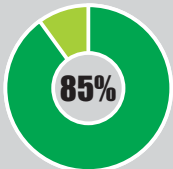


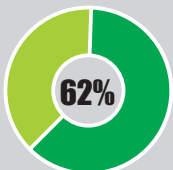
CLINICAL



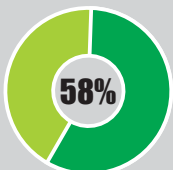
Severe
crowding



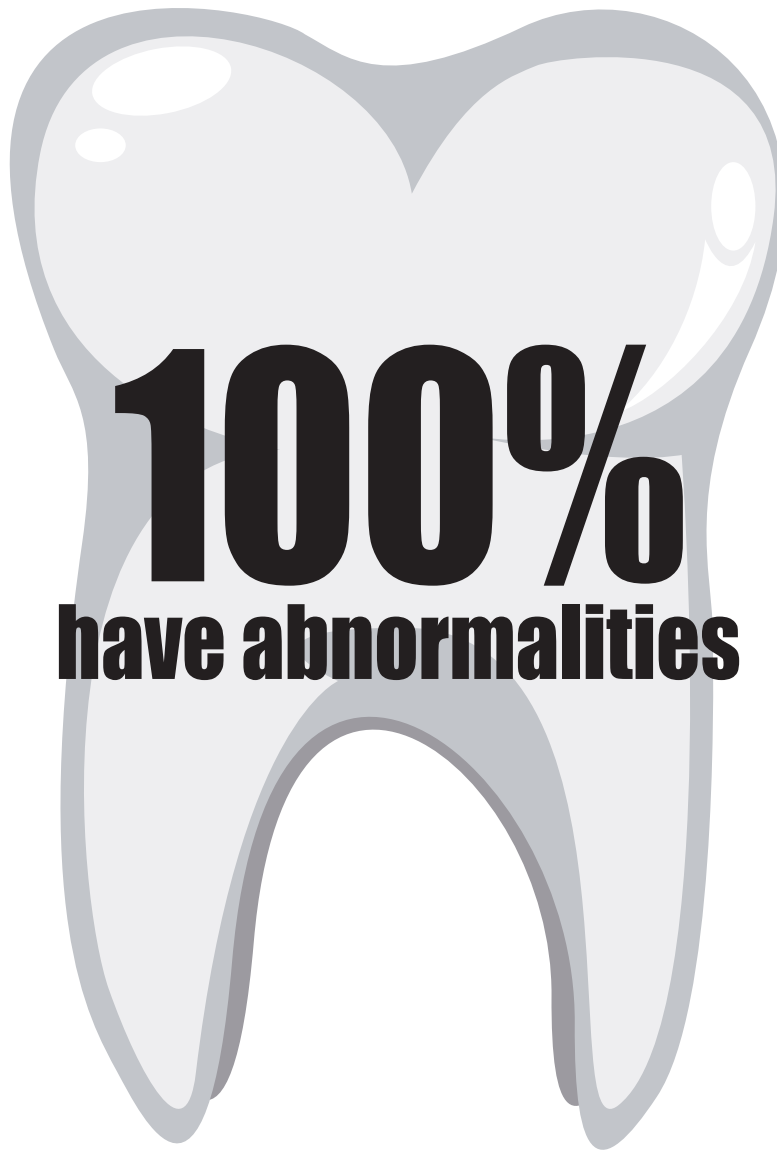
Large
front teeth



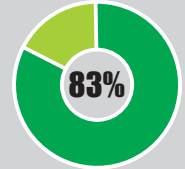
Teeth
grinding



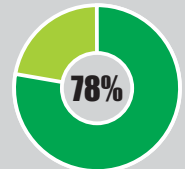
Front
teeth trauma



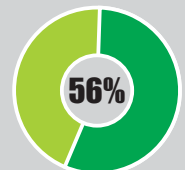RADIOGRAPHIC



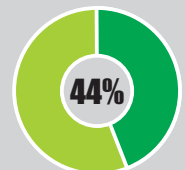
Delayed
development of
second premolars



Delayed
root formation



Severely
rotated



Other
malformations

Recommendations:

- First dental visit should be within the child's first year of life.
- See a pediatric dentist with special needs experience, such as dental teams at pediatric medical centers.
- Consider bitewings or other radiographs as necessary based on the child's risk of caries and/or cooperation.
- First dental panoramic radiograph is recommended around age 6 years or when the patient displays enough compliance for a diagnostic image.
- Orthodontist visit for all children by 7 years of age.

More information:

Including care recommendations for families and providers, please visit:
www.satb2gene.com
www.satb2gene.org